

## Evaluation of Ultrasound Guided Transversus Abdominis Plane Block for Post Operative Analgesia after Lower Segment Caeseraen Section

Palak Anilkumar Chudasama<sup>1</sup>, Milan Vijaykant Mehta<sup>2</sup>

<sup>1,2</sup>Assistant Professor, Department of Anaesthesia, Banas Medical College & Research Institute, Palanpur, Gujarat 385001, India.

### Abstract

**Background:** transversus abdominis plane (TAP) block as an effective chunk of post operative multi modal analgesia for lower abdominal surgeries. **Objective:** to evaluate the effectiveness of TAP block as a post-operative analgesia technique and usefulness in decreasing requirement of opioids as well as other pain killer medicines. **Materials and Methods:** This was a prospective study conducted from June 2018 to October 2018. Using convenient sampling technique, a total of 60 patients of American Society of Anaesthesiologists (ASA) physical status grade I or II, randomly divided into two groups: CONT group and TAP group by the sealed envelope technique. The 'control' group acted as control and was given spinal anesthesia (SA) with hyperbaric bupivacaine with a 27G BD spinal needle in lateral position. 'TAP' group' received the same spinal anesthesia and TAP block under ultrasound guidance with 23G 100-mm needle with 0.25% bupivacaine 20 ml along with dexamethasone 4 mg on each side. **Results:** Mean time to rescue analgesia in TAP & Control group was 612.8 min and 84.4 min respectively ( $p < 0.05$ ) and Mean time to rescue analgesia was 612.8 min and 84.4 min respectively ( $p < 0.05$ ). Average VAS score was higher in control group in compare to TAP group participants. Mean tramadol requirement for Group TAP was 55 mg and for the control group was 150 mg ( $p < 0.05$ ). **Conclusion:** TAP block reduces pain, prolongs the time to first analgesic request and decreases supplemental opioid analgesic requirement when used as a component of multimodal analgesic regimen for pain relief after caesarean section.

**Keywords:** Bupivacaine; Lower Segment Caesarean Section; Transversus Abdominis Plane Block; Ultrasound-Guided Regional Anaesthesia.

### How to cite this article:

Palak Anilkumar Chudasama, Milan Vijaykant Mehta. Evaluation of Ultrasound Guided Transversus Abdominis Plane Block for Post Operative Analgesia after Lower Segment Caeseraen Section. Indian J Anesth Analg. 2019;6(1):81-85.

### Introduction

Analgesic regional blocks are sometimes dangerous when given blindly [1]. Pain is very much critical and most frequent issues in which patient required medical help and decreasing pain is the main function of Anaesthesiologist as perioperative

physician [2]. Surgical complications like venous thromboembolism, respiratory complications and prolonged hospital stay can be avoid by post-operative analgesia. Post-operative analgesia must be effective and safe to consequential pain and discomfort are occurring mostly after lower section caesarean delivery (LSCS) [3,4].

**Corresponding Author:** Milan Vijaykant Mehta, Assistant Professor, Department of Anaesthesia, Banas Medical College & Research Institute, Palanpur, Gujarat 385001, India.

**E-mail:** milan.aaryen@gmail.com

**Received on** 14.10.2018, **Accepted on** 14.11.2018

Discussion was continuing from last many years on transversus abdominis plane (TAP) block as an effective chunk of post-operative multi-modal analgesia for lower abdominal surgeries. TAP cater the analgesia to the parietal peritoneum and anterior abdominal wall by blocking the nerves traversing between the transversus abdominis and internal oblique muscle [5,6]. Nowadays, ultrasound to guide injection of the local anaesthetic become more effective method as TAP block [7,8]. Efficacy of TAP block depends on concentration and the higher volume of the injected local anaesthetic is favour to dissemination more toward paravertebral spaces and block more nerves [9,10,11]. This study was undertaken to evaluate the effectiveness of TAP block as a post operative analgesia technique and usefulness in decreasing requirement of opioids as well as other pain killer medicines.

## Material and Methods:

### *Study setting and duration*

This study was conducted in department of Anesthesiology within the premises of civil hospital Palanpur, BMCRI from June 2018 to October 2018.

### *Study design and study population*

This was a prospective study designed to compare the effect of post-operative analgesia of TAP block with other pain killer medicines. A total of 60 adult patients of American Society of Anaesthesiologists (ASA) physical status grade I or II, randomly divided into two groups: CONT group and TAP group by the sealed envelope technique. The 'control' group acted as control and was given spinal anesthesia (SA) with hyperbaric bupivacaine with a 27G BD spinal needle in lateral position. They were immediately turned in supine position. Patients in 'TAP' group received the same spinal anesthesia, but after completion of surgery and before applying dressing on the wound, were also given TAP block under ultrasound guidance with 23G 100-mm needle with 0.25% bupivacaine 20 ml along with dexamethasone 4 mg on each side after informed consent. Pain score was monitored in the postoperative period, every hour for 4 h and 2 hourly for next 4 h and then at 12, 18, 24, 36, and 48 h with visual analog scale (VAS) from 0 to 10 with 0 being no pain and 10 being maximum pain

they could imagine. When the pain score came above 4, the patient was given injection diclofenac sodium 75 mg and time to rescue analgesia was noted. Vital parameters were monitored every 10 min during intraoperative period and half-hourly for 24 h in the postoperative period. All the patients in ASA-III or above, who were unwilling, allergic to LA, on anticoagulants, and those with local infection in the thigh were excluded from the study. All the patients were randomly allocated into one of the two groups using computer generated random number table. Hence each group contained a total of 30 patients.

### *Transversus abdominis plane block*

After local cleaning and draping, high frequency linear probe was kept horizontally on the flank at the level of umbilicus in anterior axillary line. All the three layers of abdominal muscles were identified and a 23 g 100 mm needle attached with local anesthetic mixture with a 50 mm extension line was introduced by in-plane technique. When the tip of the needle reached the fascia between IO and TA, after careful aspiration to rule out intravascular placement, a test injection of 0.5 ml was made, opening up of TAP plane was looked for and needle adjusted if required accordingly and test injection repeated, when the TAP plane is seen opening up, the whole amount of drug was injected. The same procedure was repeated on the other side.

### *Data analysis*

Qualitative data were expressed as percentages and proportions. Quantitative data were expressed as mean and standard deviation. The differences between two groups with respect to continuous variables were analysed using unpaired t-test while categorical variables were analysed using chi-square test. All the statistical tests were performed in Epi Info 3.5.1 software by CDC, USA [6]. P value <0.05 was considered as statistically significant while P value <0.01 was considered as statistically highly significant.

### *Ethical consent*

Before proceeding with study, appropriate ethical clearance was obtained from Hospital Ethics Committee. Each patient was included in the study only after informed consent.

**Result**

**Table 1:** Demographic variables of study participants (N=60)

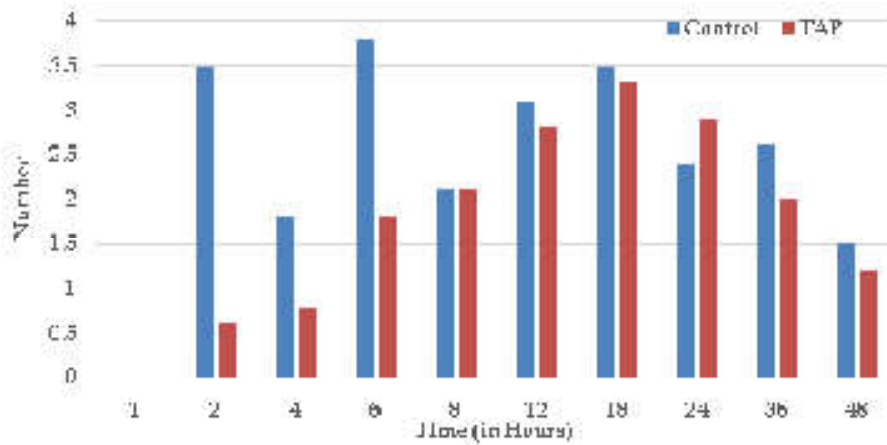
Variables	TAP Group (n=30) (Mean±SD)	Control Group (n=30) (Mean±SD)	P value
Age (in years)	28.4±5.1	29.4±4.8	0.32
Weight (in kg)	59.5±8.8	59.4±6.1	0.8
Height (in cm)	152.4±4.8	151.9±3.9	0.35
BMI (kg/m <sup>2</sup> )	26.8±3.3	26.1±4.1	0.62

Table 1 shows that mean age of TAP and Control group was 28.4 years with 5.1 SD and 29.4 years with 4.8 SD respectively. Mean weight of TAP and Control group was 59.5 kg years with 8.8 SD and 59.4 kg with 6.1 SD respectively. Mean height of TAP and Control group was 152.4 cm with 4.8 SD and 151.9 cm with 3.9 SD respectively. Mean BMI of TAP and Control group was 26.8 kg/m<sup>2</sup> with 3.3 SD and 26.1 kg/m<sup>2</sup> with 4.1 SD respectively. But difference between TAP & Control group regarding age, weight, height and BMI was statistically not significant (p>0.05).

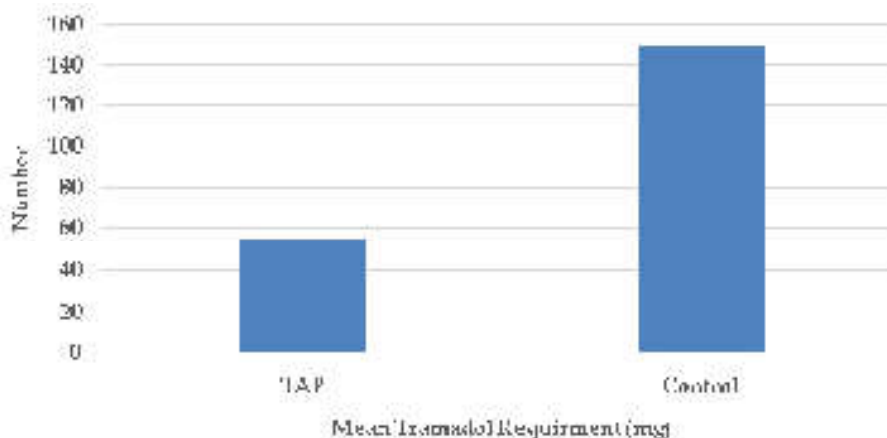
**Table 2:** Clinical variables of study participants (N=60)

Variables	TAP Group	Control Group	P value
ASA Grade			
I	3 (10.0%)	4 (13.3%)	0.56
II	27 (90.0%)	26 (86.7%)	
Dose of Bupivacaine H (mg) (mean±SD)	13.6±0.8	12.4±0.6	0.85
Duration of anaesthesia (min) (mean±SD)	71.3±12.4	74.1±15.7	0.4
Duration of surgery (min) (mean±SD)	50.0±7.3	54.7±9.0	0.03
Mean time to rescue analgesia	612.8±48.0	84.4±6.7	0.0001

Table 2 shows that most of participants (90.0% & 86.7%) of TAP and control group was belonged to ASA grade II and difference was statistically not significant (p>0.05). Mean dose of hyperbaric bupivacaine consumed in TAP & Control group was 13.6 mg and 12.4 mg respectively and difference was statistically not significant (p>0.05). Mean duration of anesthesia in TAP & Control group was 71.3 min and 74.1 min respectively and difference



**Fig. 1:** Average post-operative Visual Analog Scale (VAS) among study groups (N=60)



**Fig. 2:** Mean tramadol requirement in milligrams in the first 24 h after caesarean delivery

was statistically not significant ( $p > 0.05$ ). Mean duration of surgery in TAP & Control group was 48.5 min and 54.7 min respectively and difference was statistically significant ( $p < 0.05$ ). Mean time to rescue analgesia in TAP & Control group was 612.8 min and 84.4 min respectively and difference was statistically significant ( $p < 0.05$ ).

Figure 1 shows the post-operative mean VAS score of TAP and control groups. Average VAS score was higher in control group in compare to TAP group participants.

Figure 2 shows mean post-operative requirement of tramadol (in mg) in 24 hours after surgery. Mean tramadol requirement for Group TAP was 55 mg and for the control group was 150 mg, which was statistically significant (t value = 8.5,  $p < 0.001$ ).

## Discussion

Following LSCS surgery, Post-operative analgesia is helpful for maternal satisfaction and also prevent the harmful effect of other pain killers on the new born. Many times observed that neuraxial opioids have many side effects like nausea and pruritus which resulted in patient dissatisfaction in spite of it provides excellent analgesia [12]. TAP block caters superior analgesia, decrease supplemental opioid analgesic requirement and decreases the incidence of opioid induced side effects [13-16].

Present study observed the demographic indicators were almost similar in both the groups and difference was statistically not significant. Similar findings were also observed in study done by Jadon A et al. [17], Naveen S et al. [2] and Adeel S et al. [11] but not comparable with the study findings done by Dwivedi D et al. [1].

Present study observed that out of enrolled cases, most of patients belonged to ASA grade II which is not correlate with the study findings done by Jadon A et al. [17]. Study found the less duration of surgery and higher time to rescue analgesia in TAP group compare to control group and this difference was statistically significant. These findings are comparable with the study done by Jadon A et al. [17], Dwivedi D et al. [1] but not comparable with the study done by Naveen S et al. [2] & Adeel A et al. [11]. Our study did not find statistically significant relation between TAP and control group regarding Dose of hyperbaric Bupivacaine & Duration of anaesthesia.

Present study observed lower VAS score among TAP group participants compare to control group participants even after 48 hours after surgery.

This finding is also supported by other similar study done by Naveen S et al. [2], Adeel S et al. [11], Jadon A et al. [17], Sivapurapu V et al. [18], Manikikar MA et al. [4], McDonnell JG et al. [13], Cansiz KH et al [19], Chansoria S et al. [20], Srivastava V et al. [21], Eslamian L et al. [22] and Abdullah FW et al. [23].

TAP block is also useful in different abdominal procedures other than LSCS such as large bowel resection, open/laparoscopic appendectomy, total abdominal hysterectomy, laparoscopic cholecystectomy, open prostatectomy, abdominoplasty with or without flank liposuction, inguinal hernia and iliac crest bone graft. Due to poor vascularity of the TAP block, its action is prolonged and less incidence of any major complications [24,25].

## Conclusion

Our study conclude that TAP block reduces pain, prolongs the time to first analgesic requirement and decreases supplemental opioid analgesic requirement when used as a component of multimodal analgesic regimen for pain relief after caesarean section. TAP block is a very good technique for postoperative analgesia after LSCS. The patients remain more pain free and likely to be more alert, leading to better mother and child bonding and likely to keep the mother more capable of doing her child-caring chores and lactation.

*Source of funding:* None

*Conflict of interest:* Not Declared

## References

1. Dwivedi D, Bhatnagar V, Goje HK, Ray A, Kumar P. Transversus abdominis plane block: A multimodal analgesia technique - Our experience. *J Mar Med Soc.* 2017;19:38-42.
2. Naveen S, Singh RK, Sharma PB, Anne S. Evaluation of transversus abdominis plane block for postoperative analgesia after lower segment cesarean section. *Karnataka Anaesth J.* 2017;3:41-4.
3. McDonnell NJ, Keating ML, Muchatuta NA, Pavy TJ, Paech MJ. Analgesia after caesarean delivery. *Anaesth Intensive Care.* 2009;37:539-51.
4. Mankikar MG, Sardesai SP, Ghodki PS. Ultrasound-guided transversus abdominis plane block for post-operative analgesia in patients undergoing caesarean section. *Indian J Anaesth.* 2016 Apr; 60(4): 253-257.

5. Charlton S, Cyna AM, Middleton P, Griffiths JD. Perioperative transversus abdominis plane (TAP) blocks for analgesia after abdominal surgery. *Cochrane Database Syst Rev.* 2010;8:CD007705.
6. Rozen WM, Tran TMN, Ashton MW, Barrington M J, Ivanusic JJ, Taylor GI. Revisiting the course of the thoracolumbar nerves: A new understanding of the innervation of the anterior abdominal wall. *Clin Anat.* 2008;21:32533.
7. Tran TM, Ivanusic JJ, Hebbard P, Barrington MJ. Determination of spread of injectate after ultrasound-guided transversus abdominis plane block: A cadaveric study. *Br J Anaesth.* 2009;102:1237.
8. Hebbard P. Subcostal transversus abdominis plane block under ultrasound guidance. *Anesth Analg.* 2008;106:6745.
9. McDonnell JG, O'Donnell BD, Farrell T, Gough N, Tuite D, Power C, et al. Transversus abdominis plane block: A cadaveric and radiological evaluation. *Reg Anesth Pain Med.* 2007;32:399404.
10. Abdul Jalil RM, Yahya N, Sulaiman O, Wan Mat WR, Teo R, Izaham A, et al. Comparing the effectiveness of ropivacaine 0.5% versus ropivacaine 0.2% for transversus abdominis plane block in providing postoperative analgesia after appendectomy. *Acta Anaesthesiol Taiwan.* 2014;52:4953.
11. Adeel S, Narayan P, Chandrashekaraiiah MM, Abuhassan KA, Elsemeeen RM, Skowronski S. Ultrasound-guided transversus abdominis plane block: An evaluation of its efficacy in reducing postoperative opioid requirements in caesarean section. *J Obstet Anaesth Crit Care.* 2017;7:81-4.
12. Farragher RA, Laffey JG. Postoperative pain management following caesarean section. In: Shorten G, Carr D, Harmon D, et al., editors. *Postoperative pain management: an evidence-based guide to practice.* 1st ed. Philadelphia:Saunders Elsevier; 2006.p.225-8.
13. McDonnell JG, Curley G, Carney J, Benton A, Costello J, Maharaj C, et al. The analgesic efficacy of transversus abdominis plane block after caesarean delivery: a randomized controlled trial. *Obstetric Anesthesiol.* 2008;106(1):186-91.
14. Baaj JM, Alsattli RA, Majaj HA, Babay ZA, Thallaj AK. Efficacy of ultrasound-guided transversus abdominis plane (TAP) block for postcaesarean section delivery analgesia-a double-blind, placebo-controlled, randomized study. *Middle East J Anesthesiol.* 2010;20:821-6.
15. Tan TT, Teoh WH, Woo DC, Ocampo CE, Shah MK, Sia AT. A randomised trial of the analgesic efficacy of ultrasound-guided transversus abdominis plane block after caesarean delivery under general anaesthesia. *Eur J Anaesthesiol.* 2012;29:88-94.
16. Kanazi GE, Aouad MT, Abdallah FW, et al. The analgesic efficacy of subarachnoid morphine in comparison with ultrasound-guided transversus abdominis plane block after caesarean delivery: a randomized controlled trial. *Anesth Analg.* 2010;111:475-81.
17. Jadon A, Jain P, Chakraborty S, Motaka M, Parida SS, Sinha N. Role of ultrasound guided transversus abdominis plane block as a component of multimodal analgesic regimen for lower segment caesarean section: a randomized double blind clinical study. *BMC Anesthesiology.* 2018;18:53.
18. Sivapurapu V, Vasudevan A, Gupta S, Badhe AS. Comparison of analgesic efficacy of transversus abdominis plane block with direct infiltration of local anesthetic into surgical incision in lower abdominal gynecological surgeries. *J Anaesthesiol Clin Pharmacol.* 2013;29:71-5.
19. Cansiz KH, Yedekci AE, Sen H, Ozkan S, Dagli G. The effect of ultrasound guided transversus abdominis plane block for caesarean delivery on postoperative analgesic consumption. *Gulhane Med J.* 2015;57:121-4.
20. Chansoria S, Hingwe S, Sethi A, Singh R. Evaluation of transversus abdominis plane block for analgesia after caesarean section. *J Recent Adv Pain.* 2015;1:13-7.
21. Srivastava U, Verma S, Singh TK, Gupta A, Saxsena A, Jagar KD. Efficacy of transversus abdominis plane block for post caesarean delivery analgesia: A double-blind, randomized trial. *Saudi J Anaesth.* 2015 Jul-Sep;9(3):298-302.
22. Eslamian L, Jalili Z, Jamal A, Marsoosi V, Movafegh A. Transversus abdominis plane block reduces postoperative pain intensity and analgesic consumption in elective caesarean delivery under general anesthesia. *J Anesth.* 2012;26:334-8.
23. Abdallah FW, Halpern SH, Margarido CB. Transversus abdominis plane block for postoperative analgesia after Caesarean delivery performed under spinal anesthesia? A systematic review and meta-analysis. *Br J Anaesth.* 2012;109:679-87.
24. Bharti N, Kumar P, Bala I, Gupta V. The efficacy of a novel approach to transversus abdominis plane block for postoperative analgesia after colorectal surgery. *Anesth Analg.* 2011;112:1504-8.
25. Niraj G, Searle A, Mathews M, Misra V, Baban M, Kiani S, et al. Analgesic efficacy of ultrasound-guided transversus abdominis plane block in patients undergoing open appendectomy. *Br J Anaesth.* 2009;103:601-5.

# REDKART.NET

(A product of RF Library Services (P) Limited)  
(Publications available for purchase: Journals, Books, Articles and Single issues)  
(Date range: 1967 to till date)

The Red Kart is an e-commerce and is a product of RF Library Services (P) Ltd. It covers a broad range of journals, Books, Articles, Single issues (print & Online-PDF) in English and Hindi languages. All these publications are in stock for immediate shipping and online access in case of online.

**Benefits of shopping online are better than conventional way of buying.**

1. Convenience.
2. Better prices.
3. More variety.
4. Fewer expenses.
5. No crowds.
6. Less compulsive shopping.
7. Buying old or unused items at lower prices.
8. Discreet purchases are easier.

URL: [www.redkart.net](http://www.redkart.net)